

# Association of Localized Intravascular Coagulopathy With Venous Malformations

Anne Dompmmartin, MD; Aurélie Acher, MD; Pascal Thibon, MD; Sébastien Tourbach, MD; Cédric Hermans, MD, PhD; Véronique Deneys, MD; Ben Pocock, MD; Agnès Lequerrec, MPhSc; Daniel Labbé, MD; Marie-Thérèse Barrellier, MD; Romain Vanwijck, MD, PhD, FRCS; Miikka Vikkula, MD, PhD; Laurence M. Boon, MD, PhD

**Objective:** To determine which venous malformations (VMs) are at risk for coagulopathy. Venous malformations are slow-flow vascular malformations present at birth, and localized intravascular coagulopathy (LIC) causes pain and thrombosis within a lesion and severe bleeding during surgical procedures.

**Design:** Prospective convenience sample accrued from 2 multidisciplinary sites in Brussels, Belgium, and Caen, France.

**Participants:** The study population comprised 140 patients with clinical data and coagulation parameters. Magnetic resonance imaging was performed for 110 patients.

**Main Outcome Measure:** Measurement of D-dimer levels.

**Results:** Of the 140 participants, 59 (42%) showed high D-dimer levels, 36 (61%) of whom had levels higher than 1.0 µg/mL. Six of the participants had low fibrinogen levels. In univariate analysis, large surface, presence of pal-

pable phleboliths, and truncal localization were associated with high D-dimer levels. In the multivariate analysis, only large surface area and presence of phleboliths remained independently associated with high D-dimer levels. Severe LIC, characterized by concomitant low fibrinogen level, was associated with extensive venous malformations of the extremities.

**Conclusions:** Localized intravascular coagulopathy is statistically significantly associated with large and/or deep venous malformations that affect any location, which can have a palpable phlebolith. These patients are at risk of local pain due to thrombosis. Lesions with elevated D-dimer levels associated with low fibrinogen levels (severe LIC) commonly affect an extremity and have a high risk of hemorrhage. Low-molecular-weight heparin can be used both to treat the pain caused by LIC and to prevent decompensation of severe LIC to disseminated intravascular coagulopathy.

*Arch Dermatol.* 2008;144(7):873-877

## Author Affiliations:

Departments of Dermatology (Drs Dompmmartin, Acher, and Barrellier), Hygiene (Dr Thibon), Hematology (Ms Lequerrec), and Plastic Surgery (Dr Labbé), Université de Caen Basse Normandie, Centre Hospitalier Universitaire Caen, Caen, France; Division of Plastic Surgery, Center for Vascular Anomalies (Drs Tourbach, Pocock, Vanwijck, and Boon) and Hematosis and Thrombosis Unit, Division of Haematology & Laboratory of Thrombosis and Haemostasis, Department of Biological Chemistry (Drs Hermans and Deneys), Université catholique de Louvain, Cliniques Universitaires St Luc, Brussels, Belgium; and Laboratory of Human Molecular Genetics, Université catholique de Louvain, Institut de Duve, Brussels (Drs Vikkula and Boon).

**V**ASCULAR MALFORMATIONS are localized or diffuse lesions caused by errors in embryonic development. They are subdivided anatomically and rheologically into slow-flow and fast-flow lesions. Among patients referred to centers for vascular anomalies, venous malformations (VMs)

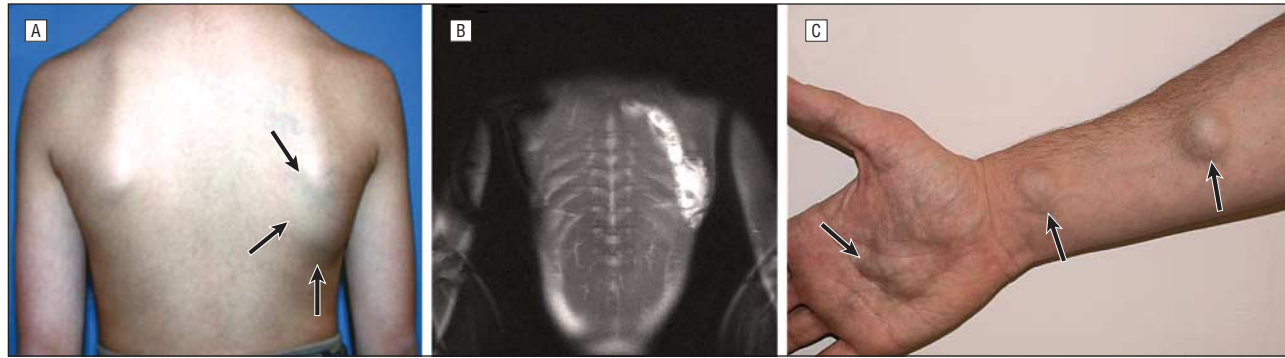
*See also pages 861 and 922*

represent more than 50% of cases.<sup>1-4</sup> These slow-flow lesions present as bluish or purple lesions, which are mainly localized on the skin and mucosa but can present in any anatomic location, tissue, or organ.<sup>5-7</sup> Most of them are asymptomatic, but swelling and pain are common. Due to blood stagnation, thrombosis can occur, leading to phlebolith formation.<sup>8,9</sup>

In a retrospective study, a coagulation disorder named localized intravascular co-

agulopathy (LIC), characterized by elevated D-dimer level, was observed in 19 of 24 patients with extensive and painful VM of the limbs.<sup>10,11</sup> Six of the patients had severe LIC characterized by concomitant low fibrinogen level and variable platelet count.<sup>11</sup> Localized intravascular coagulopathy needs to be distinguished from Kasabach-Merritt phenomenon, which is characterized by a predominant platelet consumption.<sup>11</sup>

Our experience with the index case of a child, who was operated on 3 times for functional impairment due to her VM, led to this study of the frequency of blood coagulation disturbance among VMs and the type of VMs that are associated with it. The first procedure, which was performed without low-molecular-weight heparin (LMWH), was complicated by perioperative disseminated intravascular coagulopathy (DIC) marked by bleeding and consumption of platelets and coagulation factors. During the second procedure, fibrinogen was injected before the surgical



**Figure 1.** Venous malformation (VM) in 2 patients. A, Large, unifocal, truncal, skin-colored, flat venous malformation (arrows) in a 13-year-old male patient, which was associated with a high D-dimer level ( $>1.0 \mu\text{g/mL}$ ) and palpable phleboliths. B, Magnetic resonance imaging shows muscle involvement of this deep VM. C, Multifocal VMs (arrows) on the right arm of a 28-year-old male patient with a high D-dimer level ( $7.8 \mu\text{g/mL}$ ). Additional lesions are present on the trunk and other limbs.

incision was made and helped to control DIC. Preoperative and postoperative treatment with LMWH prevented DIC during the third procedure.

## METHODS

We conducted a prospective study from January 2004 to December 2005 in 2 multidisciplinary centers for vascular anomalies (Brussels, Belgium, and Caen, France). This study was approved by the ethics committee of Université catholique de Louvain, Brussels. All participants signed an informed consent form.

## PATIENTS

All 141 patients presenting with a mucosal or cutaneous and/or subcutaneous VM diagnosed by either multidisciplinary team were included. The diagnosis was made by clinical evaluation and confirmed by Doppler ultrasonography, if necessary. Magnetic resonance imaging with T1- and T2-weighted and fat-saturated sequences was performed on 110 patients to evaluate the involvement of skin, muscles, and joints.

One patient with concomitant inflammatory disease was excluded. None had a malignant tumor, a history of thrombosis, or known thrombophilia or were receiving antithrombotic therapy. Patients with other vascular malformations were not included.

The remaining 140 patients were evaluated by L.M.B. (Brussels) and A.D. (Caen), and the following 9 data points were recorded:

- Clinical criteria: age; sex; number (unique or multifocal); location (limbs, head and neck, and trunk); size ( $<10 \text{ cm}^2$  or  $\geq 10 \text{ cm}^2$ ); aspect (flat or raised); color (blue or skin color); and palpable phleboliths.
- Radiological criterion: depth of involvement (subcutis, muscles, and joints).

Despite the use of aspirin or analgesic or nonsteroidal anti-inflammatory drugs, 22 of the 140 subjects had elevated D-dimer levels and pain impairing their daily life. These patients were treated by subcutaneous injections of enoxaparin ( $100 \text{ anti-Xa U/kg/d}$  for 20 days).

## PROCEDURES

At the initial examination and at follow-up every 1 to 3 months for 1 to 2 years, blood was drawn from a peripheral vein not involved by the VM for coagulation tests. Platelets (reference

range,  $150\,000/\text{mL}$ - $400\,000/\text{mL}$ ) were counted in an EDTA sample using an automated instrument (Sysmex XE-2100; Roche Diagnostics, Basel, Switzerland). Prothrombin time (Thromborel S; Dade Behring, Marburg, Germany), activated partial prothrombin time (Platelin L; bioMérieux, Marcy-l'Etoile, France), and fibrinogen level (reference range,  $200$ - $450 \text{ mg/dL}$  [to convert to micromoles per liter, multiply by  $0.0294$ ]) (Fibriquick; bioMérieux) were measured in a tube containing  $0.129\text{M}$  of trisodium citrate and determined using a coagulation device (MDA 2; bioMérieux). Plasma D-dimer level (reference range,  $<0.5 \mu\text{g/mL}$  was determined using enzyme-linked immunosorbent assay (VIDAS D-Dimer New DD2; bioMérieux). For the 22 patients with painful VM treated with LMWH for 20 days, another sample for D-dimer and fibrinogen levels was drawn 10 to 21 days after the beginning of treatment and 1 month after therapy. Treatment was restarted if pain reappeared, and the patient was reevaluated every 20 days.

## STATISTICAL ANALYSIS

The statistical analysis was performed using the SAS version 9 software (SAS Institute Inc, Cary, North Carolina). Percentages of positive and negative D-dimer test results for each item (age, sex, number, location, size, aspect, color, phleboliths, and depth of involvement) were compared by univariate analysis using the  $\chi^2$  or Fisher test. For quantitative variables, the paired *t* test was used. Logistic regression model was used for the variables significantly associated with a positive D-dimer test result in the univariate analysis. The threshold of significance was 0.20 or less. The comparison between D-dimer levels before and after treatment was conducted using the Wilcoxon test. For all the statistical analyses,  $P < .05$  was considered statistically significant.

## RESULTS

Among the 140 patients, 44 were male and 96 were female, aged 10 months to 78 years, with a mean (SD) age of 26.8 (16.4) years and a median age of 22 years. Most of the VMs were limited to a single anatomical region, such as a limb, trunk or head, and neck (**Figure 1A** and **B**) ( $n=129$ ), yet 6 extended to 2 regions (**Table 1**). Patients with small, numerous, and disseminated lesions (multifocal) (**Figure 1C**) were rare ( $n=5$ ).

Of the 140 patients, 59 (42%) had repeatedly elevated D-dimer levels, 36 (61%) of whom had levels higher than  $1.0 \mu\text{g/mL}$ . Fibrinogen levels were normal in 134 patients

**Table 1. Localization of Venous Malformations (VMs) in 140 Patients**

Localization	No. of VMs
Head and neck	52
Trunk	19 <sup>a</sup>
Limbs	70 <sup>a</sup>
Multifocal	5

<sup>a</sup>Including 6 extensive VMs with more than 1 location.

with normal prothrombin time, activated partial prothrombin time, and platelet counts. Six patients had low fibrinogen levels (85-176 mg/dL), only 1 of which was below 100 mg/dL. These patients had very high D-dimer levels (1.9-9.0 µg/mL), and 1 had a low platelet count (114 × 10<sup>3</sup>/µL [to convert to ×10<sup>9</sup>/L, multiply by 1.0]).

Due to the low number of multifocal VMs, these 5 patients were excluded from the statistical analysis, resulting in a final sample size of 135 subjects. There was no statistical difference between the positive and negative D-dimer test result populations for age, sex, aspect, or color of the VM (**Table 2**). Elevated D-dimer levels were statistically significantly associated with truncal localization (74%), in contrast to head and neck VMs (31%). Small size (<10 cm<sup>2</sup>) was associated with head and neck location ( $\chi^2$  test=7.78; *P*=.002). Large size (≥10 cm<sup>2</sup>) was statistically significantly associated with a positive D-dimer test result, independently of the localization, since 59% of the large VMs (≥10 cm<sup>2</sup>) had positive D-dimer test results vs 23% of small VMs (*P*<.001). Interestingly, 40 of 45 (89%) patients with diffuse and extensive VM (half or more of a limb, hemitruncal, or hemifacial) had elevated D-dimer levels. Thirty-four patients (61%) presenting with palpable phleboliths had positive D-dimer test results vs 21 (27%) of those without palpable phleboliths (*P*<.001).

The comparison between VM depth and D-dimer levels was done for the 110 patients who had undergone magnetic resonance imaging. In this population, we noted a strong correlation between large surface size (≥10 cm<sup>2</sup>) and deep involvement (at least 1 muscle), since 62% of the VMs with muscle involvement had a surface area of 10 cm<sup>2</sup> or larger, vs 24% of cutaneous and subcutaneous VMs with a surface area of 10 cm<sup>2</sup> or larger (*P*=.003). Large surface area and deep involvement were both statistically significantly associated with LIC (*P*=.01 for large surface and *P*=.03 for deep involvement).

In the multivariate analysis (**Table 3**), the effect of deep involvement and surface area in regard to the D-dimer levels could not be studied in the same model because of their high correlation. Thus, they were compared in 2 different models with the presence of palpable phleboliths and truncal localization. Surface area and palpable phleboliths remained independently associated with elevated D-dimer levels with an odds ratio of 2.82 (95% confidence interval, 1.24-6.39) and 3.16 (95% confidence interval, 1.40-7.09), respectively. The effect of truncal location was not found. When examining the effect of deep involvement, the adjusted odds ratio was 3.09

**Table 2. Univariate Analysis Performed on 135 Patients With Venous Malformations<sup>a</sup>**

Variable	D-Dimer Level, µg/mL		<i>P</i> Value
	<0.5	≥0.5	
Sex			
Male	22 (51)	21 (49)	.19
Female	58 (63)	34 (37)	
Age, median (SD), y	28 (16)	25 (17)	.48
Localization <sup>b</sup>			
Head and neck	36 (69)	16 (31)	.06
Trunk	5 (26)	14 (74)	.002
Limbs	39 (56)	31 (44)	.38
Surface			
<10 cm <sup>2</sup>	53 (77)	16 (23)	<.001
≥10 cm <sup>2</sup>	27 (41)	39 (59)	
Aspect			
Flat	53 (62)	32 (38)	.34
Raised	27 (54)	23 (46)	
Color			
Blue	53 (62)	33 (38)	.46
Skin color	27 (55)	22 (45)	
Palpable phlebolith(s)			
No	58 (73)	21 (27)	<.001
Yes	22 (39)	34 (61)	

<sup>a</sup>Data are given as number (percentage) unless otherwise specified.

<sup>b</sup>Localization was studied for 141 venous malformations, since 6 patients had venous malformations affecting 2 localizations.

**Table 3. Multivariate Analysis Performed on 135 Patients With Venous Malformations**

Variable	Adjusted OR (95% CI)	<i>P</i> Value
Sex (male vs female)	1.66 (0.72-3.87)	.24
Localization: trunk	2.79 (0.81-9.55)	.10
Surface ≥10 cm <sup>2</sup>	2.82 (1.24-6.39)	.01
Palpable phlebolith(s)	3.16 (1.40-7.09)	.005

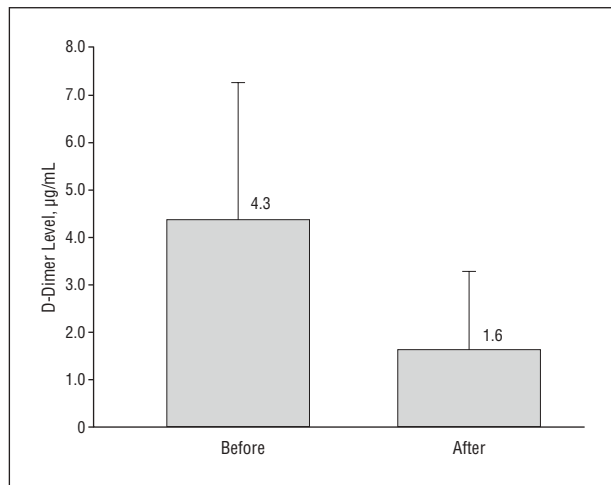
Abbreviations: CI, confidence interval; OR, odds ratio.

(95% confidence interval, 1.21-7.87). The other results were very similar to those of the model including VM surface area. This means that a VM with deep involvement or large surface area or with palpable phleboliths has a 3-times higher risk for elevated D-dimer levels. Consequently, a patient who has a deep or a large VM with palpable phleboliths has a 9-times higher risk for LIC.

Mean (SD) D-dimer levels for the 22 patients treated with LMWH was 4.3 µg/mL (2.9 µg/mL) before treatment and 1.6 µg/mL (1.6 µg/mL) after treatment. This significant decrease in D-dimer levels (*P*<.001) was associated with rapid pain relief (**Figure 2**). Fibrinogen levels did not change in a statistically significant manner.

## COMMENT

In this prospective study, we demonstrated that coagulation abnormalities are frequent among patients with VM, since nearly half of our 140 patients (n=52 [42%]) had

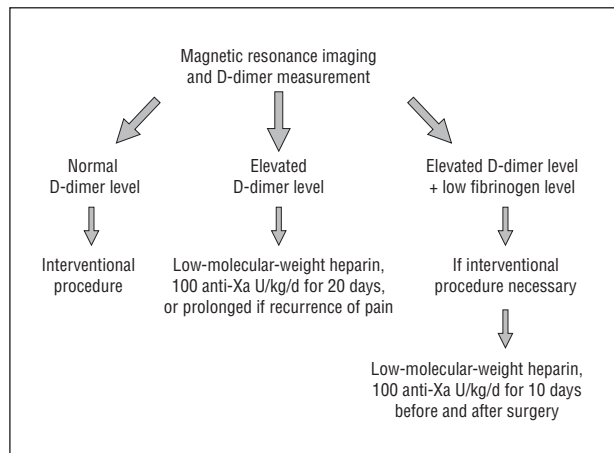


**Figure 2.** D-dimer levels, with means and standard deviations, before and after treatment with low-molecular-weight heparin for painful venous malformations.

elevated D-dimer levels and 36 patients (25%) had D-dimer levels higher than 1.0 µg/mL. In our study, elevated D-dimer levels were not associated with limb lesions, whereas truncal localization was a predictable factor in the univariate analysis. However, truncal localization was not an independent criterion in the multivariate analysis. Cervicofacial localization was not statistically significantly associated with elevated D-dimer levels either. In fact, 69% of cervicofacial VMs (n=36) had low D-dimer levels and were statistically significantly associated with small size, which is probably a reflection of facial lesions causing earlier consultation due to esthetic concerns. Large surface and deep involvement were statistically significantly associated with elevated D-dimer levels. Thus, the univariate association observed for truncal localization could be due to the large size and/or deep involvement of such lesions (Figure 1A and B). The strong statistical correlation between large surface area and deep involvement highlights the fact that large cutaneous VMs involve underlying structures.

Palpable phlebolith was an independent criterion that was also associated with a positive D-dimer test result. However, the incidence of phleboliths is underestimated because deep phleboliths are only seen on radiological examination. The presence of palpable phleboliths in a large or deep VM increases the risk for LIC to 9-fold. None of our patients exhibited pulmonary embolism, which can be observed in Klippel-Trenaunay syndrome but has never been reported in a patient with an isolated VM.<sup>12</sup>

Constant activation of coagulation due to blood stagnation within the distorted and enlarged slow-flow venous channels leads to the production of thrombin and the conversion of fibrinogen into fibrin. The subsequent fibrinolysis is reflected by elevated levels of fibrin degradation products, such as D-dimer epitopes. Such activation was named LIC.<sup>10</sup> It can sometimes cause localized hemorrhage and/or thrombosis (phleboliths) with normal coagulation factor (prothrombin time and activated partial prothrombin time) levels and platelet count. Interestingly, 80% of our multifocal VMs (n=4 of 5) were



**Figure 3.** Management scheme for painful venous malformations.

associated with elevated D-dimer levels, although the lesions were small (<10 cm<sup>2</sup>) (Figure 1C). This could be due to the combined lesional volume or could indicate that blood stagnation may not be the only cause of the activation of coagulation. The intrinsic nature of increased coagulation in VMs is underscored by the fact that LIC can be induced by sclerotherapy with dehydrated ethanol or sodium tetradecyl sulfate in patients with VM who have normal preoperative D-dimer levels.<sup>13</sup>

We were surprised by the extremely high level of D-dimers in 25% of our patients. To our knowledge, VM is the only disease that can dramatically increase D-dimer levels in otherwise healthy patients. Similar levels are only seen in life-threatening disorders, such as pulmonary embolism, malignant tumors, and inflammatory diseases. Although LIC is well tolerated in everyday life, systemic activation of coagulation can occur during surgical resection as DIC, which is marked by consumption of platelets, fibrinogen, and coagulation factors, with increased prothrombin time and dramatic perioperative bleeding. Remarkably, 6 patients had extensive, diffuse, painful VMs involving muscles and localized on the limbs (n=4), the trunk (n=1), or multifocally (limb + trunk; n=1). Mazoyer and coauthors<sup>11</sup> noted that 6 of 24 patients with a limb VM had high D-dimer levels and low fibrinogen levels, reinforcing the observation that VMs with severe LIC often affect an extremity.

If fibrinogen level is normal, it is not necessary to treat this chronic coagulopathy; however, painful lesions need surgical management (Figure 3). Elastic compression, when possible, is useful to minimize blood stasis. As published by others,<sup>10</sup> and in our experience, aspirin has low efficacy because, contrary to Kasabach-Merritt phenomenon, platelets are not involved in LIC.<sup>14-17</sup> Moreover, aspirin increases bleeding during surgical procedures. Oral vitamin K antagonists decrease the level of coagulation factors, but are not sufficient to prevent thrombin formation in this coagulation activation. Therefore, the only efficient treatment is LMWH, which can stop the pain due to thrombosis, as we observed in all our 22 patients with painful VM associated with elevated D-dimer levels, who were treated with LMWH.<sup>18</sup> In these patients, D-dimer levels were lowered, although not normalized. In contrast, the low fibrinogen level observed in 2 pa-



tients was normalized. Low fibrinogen level reflects high consumption due to clotting associated with high fibrinolysis and increased risk for bleeding. Therefore, these patients need careful management of LIC before any interventional procedure, such as surgery or sclerotherapy, to improve the hematological status and prevent DIC. Currently, we start preventive treatment with subcutaneous enoxaparin 10 days before any surgical procedure for a total of 20 days.

Our study demonstrates that LIC is frequently associated with VM and that large surface area, muscle involvement, and palpable phleboliths are strong predictable criteria for coagulation anomaly. This is not only true for large VMs but also for multifocal VMs. D-dimer and fibrinogen measurements and simple and inexpensive tests must be performed as part of the medical evaluation of VMs, no matter their size and location. When elevated D-dimer levels are associated with pain, LMWH is the treatment of choice. When fibrinogen level is low, most often occurring in extensive VMs affecting an extremity at least partially, the potential aggravation of LIC to DIC needs preventive management by LMWH.

**Accepted for Publication:** November 25, 2007.

**Correspondence:** Laurence M. Boon, MD, PhD, Division of Plastic Surgery, Center for Vascular Anomalies, Cliniques universitaires St Luc, Av Hippocrate 10, B-1200 Brussels, Belgium (laurence.boon@uclouvain.be).

**Author Contributions:** Dr Boon had full access to all the data in the study and takes responsibility for the integrity of the data and the accuracy of the data analysis. **Study concept and design:** Dompmartin, Vikkula, and Boon. **Acquisition of data:** Dompmartin, Acher, Tourbach, Hermans, Deneys, Pocock, Lequerrec, Labbé, Barrellier, and Boon. **Analysis and interpretation of data:** Dompmartin, Acher, Thibon, Vanwijck, Vikkula, and Boon. **Drafting of the manuscript:** Dompmartin, Vikkula, and Boon. **Critical revision of the manuscript for important intellectual content:** Dompmartin, Acher, Thibon, Tourbach, Hermans, Deneys, Pocock, Lequerrec, Labbé, Barrellier, Vanwijck, Vikkula, and Boon. **Statistical analysis:** Acher and Thibon. **Obtained funding:** Vikkula. **Administrative, technical, and material support:** Vikkula. **Study supervision:** Dompmartin, Vikkula, and Boon.

**Financial Disclosure:** None reported.

**Funding/Support:** This study was partially supported by the Interuniversity Attraction Poles initiated by the Belgian Federal Science Policy network 5/25 and 6/05; concerted Research Actions—Convention 02/07/276 of the Bel-

gian French Community Ministry; the National Institute of Health Program Project P01 AR048564-01A1; EU FW6 Integrated project LYMPHANGIOGENOMICS, LSHG-CT-2004-503573; and the FNRS (Fonds national de la recherche scientifique) (to Dr Vikkula, a “Maitre de recherches du FNRS”).

**Additional Contributions:** Guillaume Acher, MD, provided statistical help, and Liliana Niculescu, PhD, provided secretarial assistance.

## REFERENCES

1. Mulliken JB, Glowaki J. Hemangiomas and vascular malformations in infants and children: a classification based on endothelial characteristics. *Plast Reconstr Surg*. 1982;69(3):412-420.
2. Boon LM, Mulliken JB, Enjolras O, Vikkula M. Glomuvenous malformations (glomangioma) and venous malformation: distinct clinicopathologic and genetic entities. *Arch Dermatol*. 2004;140(8):971-976.
3. Vikkula M, Boon LM, Mulliken JB. Molecular basis of vascular anomalies. *Trends Cardiovasc Med*. 1998;8(7):281-292.
4. Brouillard P, Vikkula M. Vascular malformations: localized defects in vascular morphogenesis. *Clin Genet*. 2003;63(5):340-351.
5. Enjolras O, Mulliken JB. The current management of vascular birthmarks. *Pediatr Dermatol*. 1993;10(4):311-333.
6. Buckmiller LM. Update on hemangiomas and vascular malformations. *Curr Opin Otolaryngol Head Neck Surg*. 2004;12(6):476-487.
7. Casanova D, Boon LM, Vikkula M. Venous malformations: clinical characteristics and differential diagnosis. *Ann Chir Plast Esthet*. 2006;51(4-5):373-387.
8. Hein KD, Mulliken JB, Kozakewich HP, Upton J, Burrow P. Venous malformations of skeletal muscle. *Plast Reconstr Surg*. 2002;110(7):1625-1635.
9. Hermans C, Dessomme B, Lambert C, Deneys V. Venous malformations and coagulopathy. *Ann Chir Plast Esthet*. 2006;51(4-5):388-393.
10. Enjolras O, Ciabrini D, Mazoyer E, Laurian C, Herbreteau D. Extensive pure venous malformations in the upper or lower limb: a review of 27 cases. *J Am Acad Dermatol*. 1997;36(2, pt 1):219-225.
11. Mazoyer E, Enjolras O, Laurian C, Houdart E, Drouhet L. Coagulation abnormalities associated with extensive venous malformations of the limbs: differentiation from Kasabach-Merritt syndrome. *Clin Lab Haematol*. 2002;24(4):243-251.
12. Huiras EE, Barnes CJ, Eichenfield LF, Pelech AN, Drolet BA. Pulmonary embolism associated with Klippel-Trenaunay syndrome. *Pediatrics*. 2005;116(4):e596-e600.
13. Mason KP, Neufeld EJ, Karian VE, Zurakowski D, Koka BV, Burrows PE. Coagulation abnormalities in pediatric and adult patients after sclerotherapy or embolization of vascular anomalies. *AJR Am J Roentgenol*. 2001;177(6):1359-1363.
14. Enjolras O, Wassef M, Mazoyer E, et al. Infants with Kasabach-Merritt syndrome do not have “true” hemangiomas. *J Pediatr*. 1997;130(4):631-640.
15. Sarkar M, Mulliken J, Kozakewich HP, Robertson RL, Burrows PE. Thrombocytopenic coagulopathy Kasabach-Merritt phenomenon is associated with hemangioendothelioma and not with common infantile hemangioma. *Plast Reconstr Surg*. 1997;100(6):1377-1385.
16. Hall GW. Kasabach-Merritt syndrome: pathogenesis and management. *Br J Haematol*. 2001;112(4):851-862.
17. Ezekowitz RA, Mulliken JB, Folkman J. Interferon alpha 2a therapy in life threatening hemangioma in infancy. *N Engl J Med*. 1992;326(22):1456-1463.
18. Elly GL. Heparin therapy for bleeding associated with hemangioma. *Surgery*. 1969;65(6):894-897.